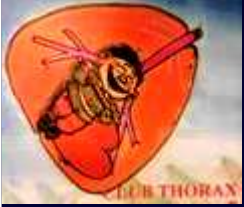



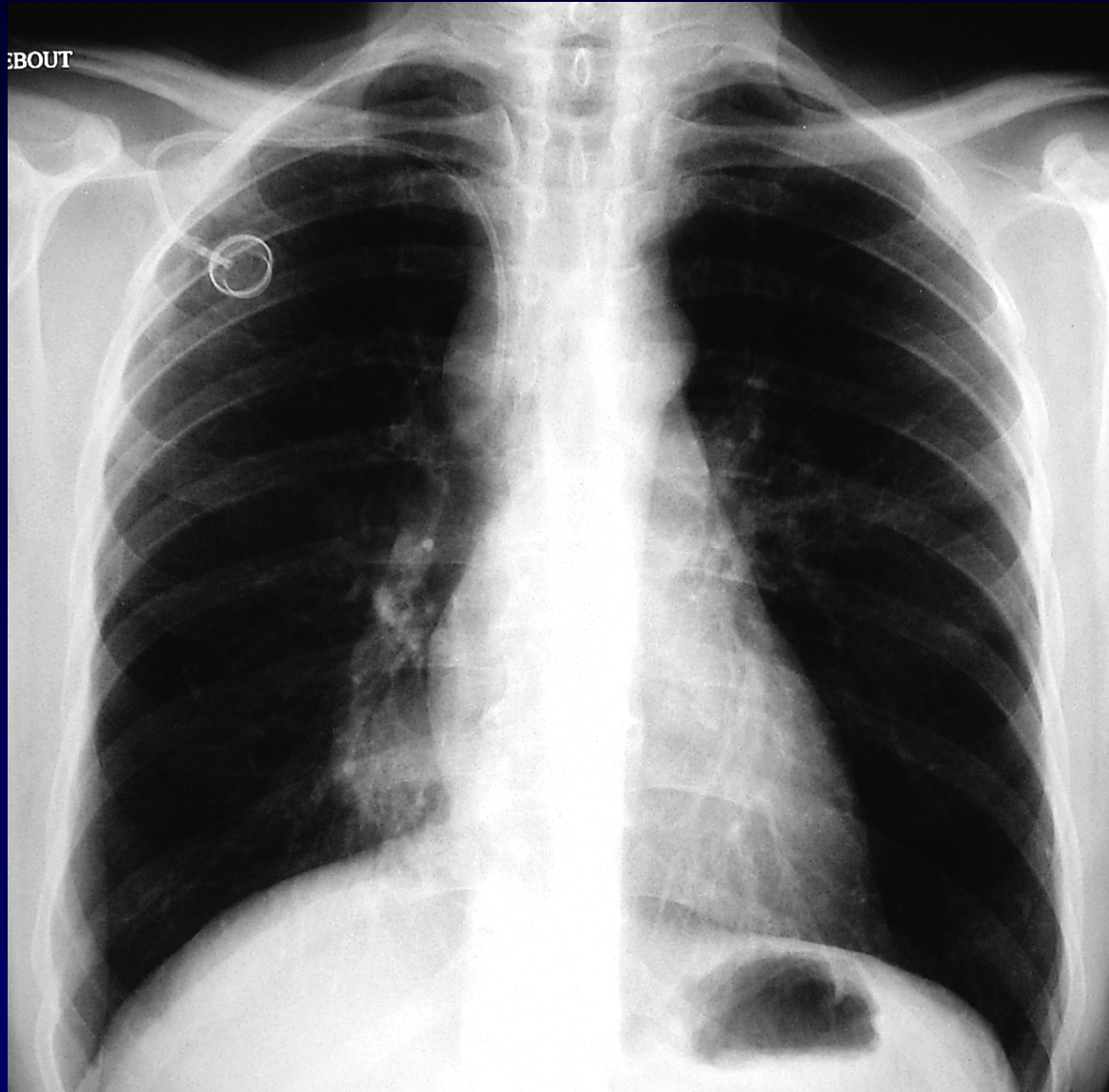
# Dispositifs veineux implantables en position aberrante

**M EL HAJJAM**  
**P LACOMBE**

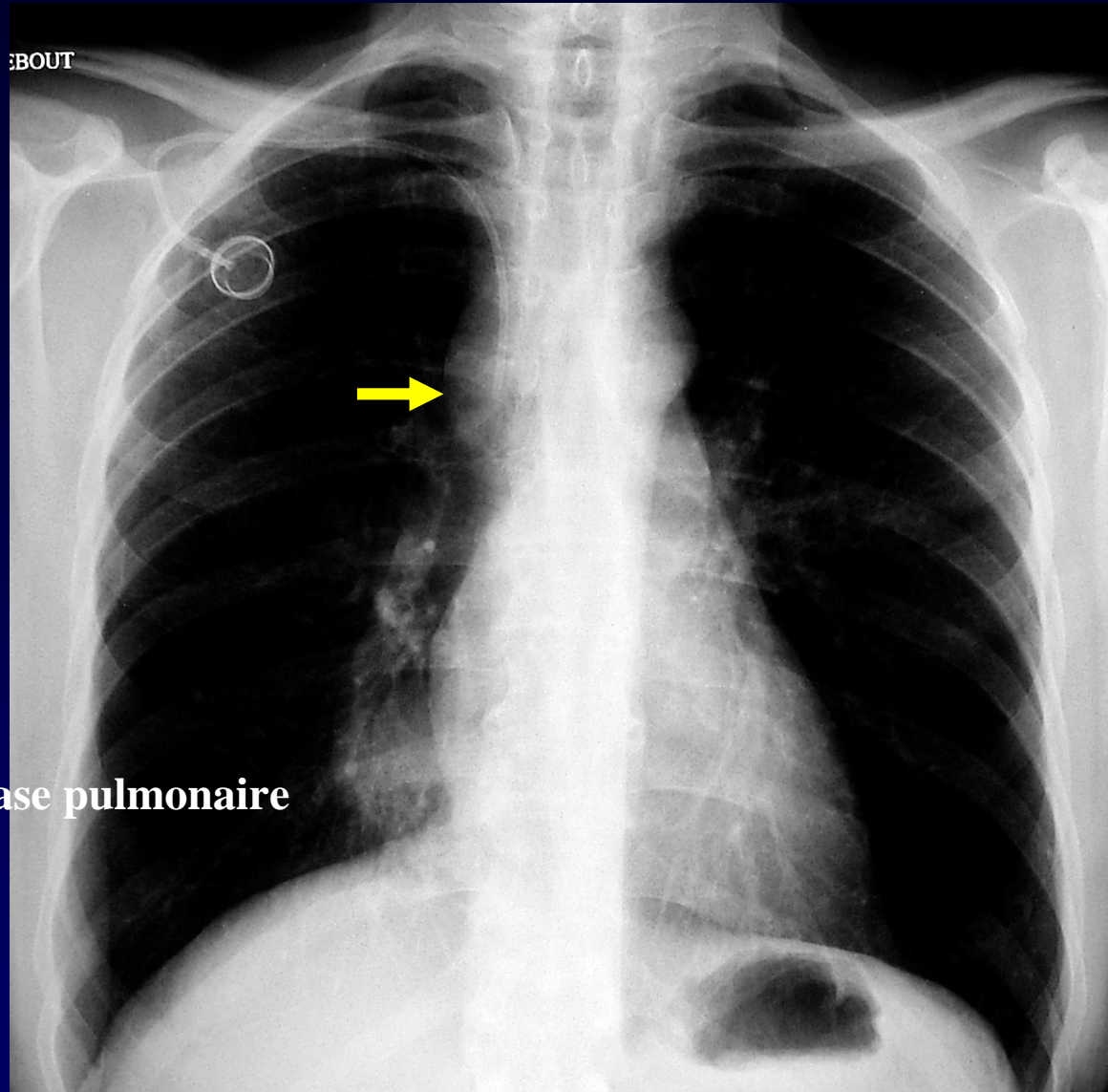


ABOUT

**Cas 1**



**Qu'en pensez vous ?**

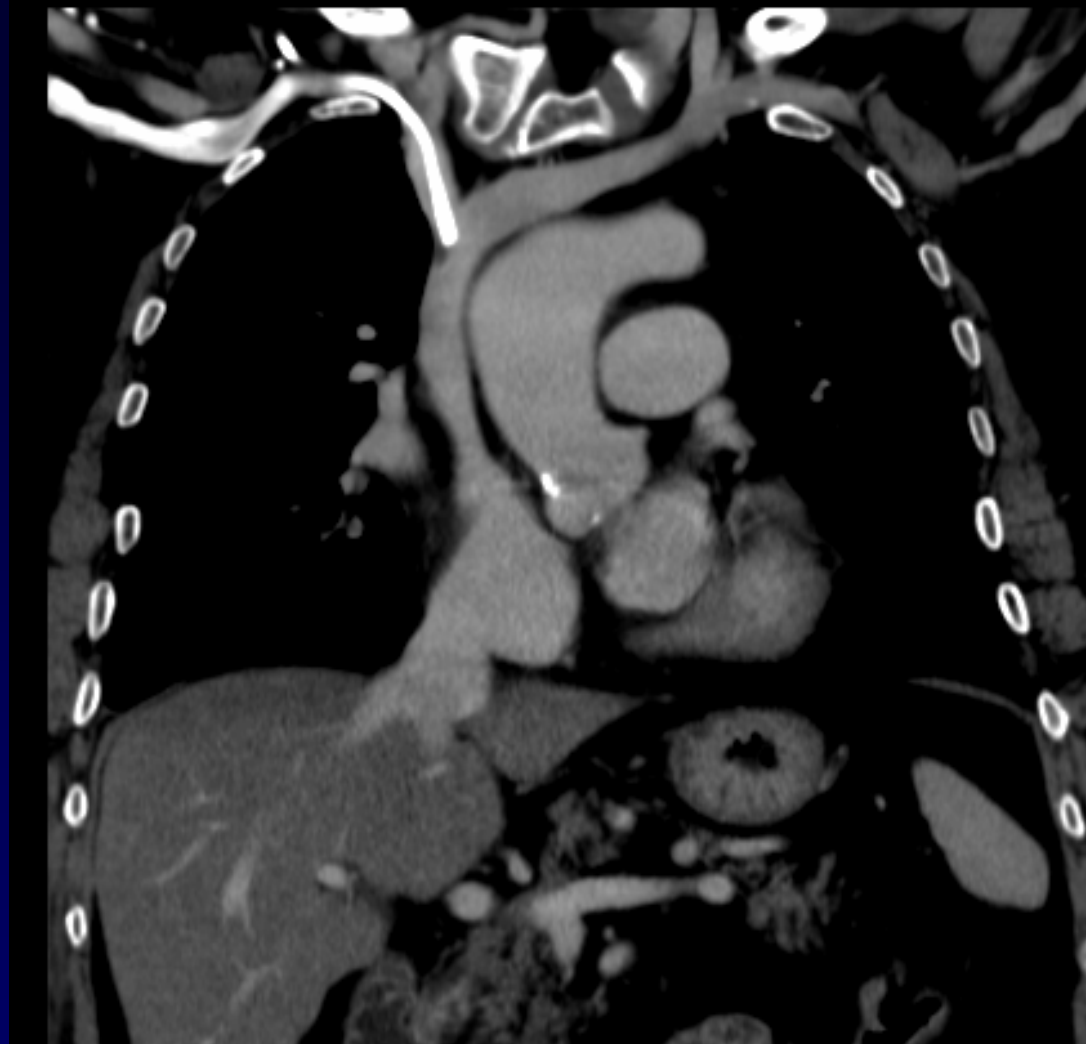


Métastase pulmonaire

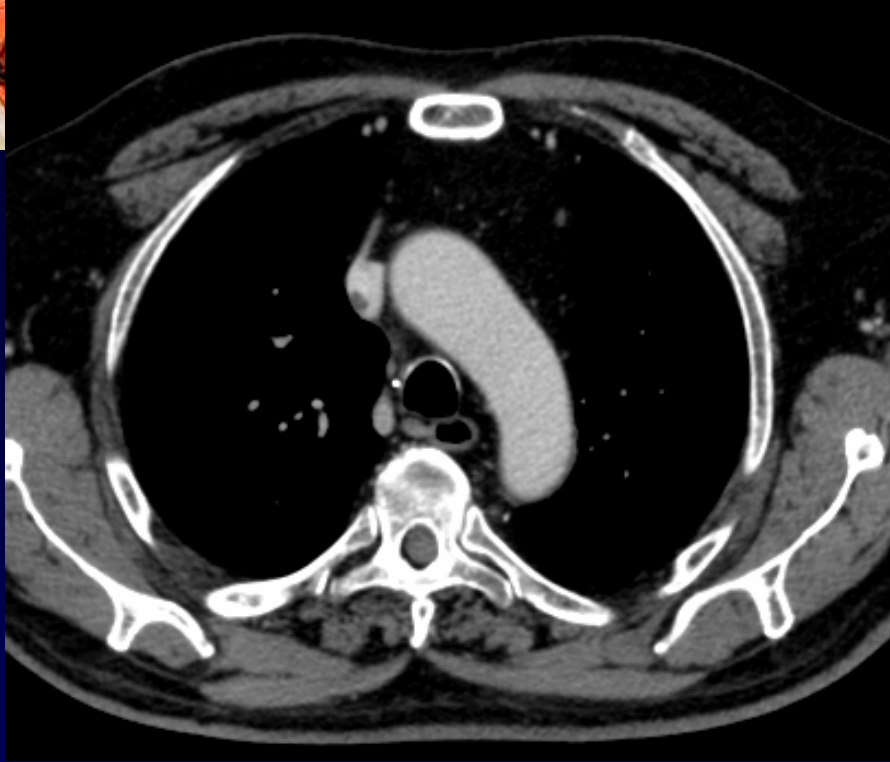**DVI court** : Syndrome cave supérieur  
Dilatation de la crosse azygos



## Cas 2

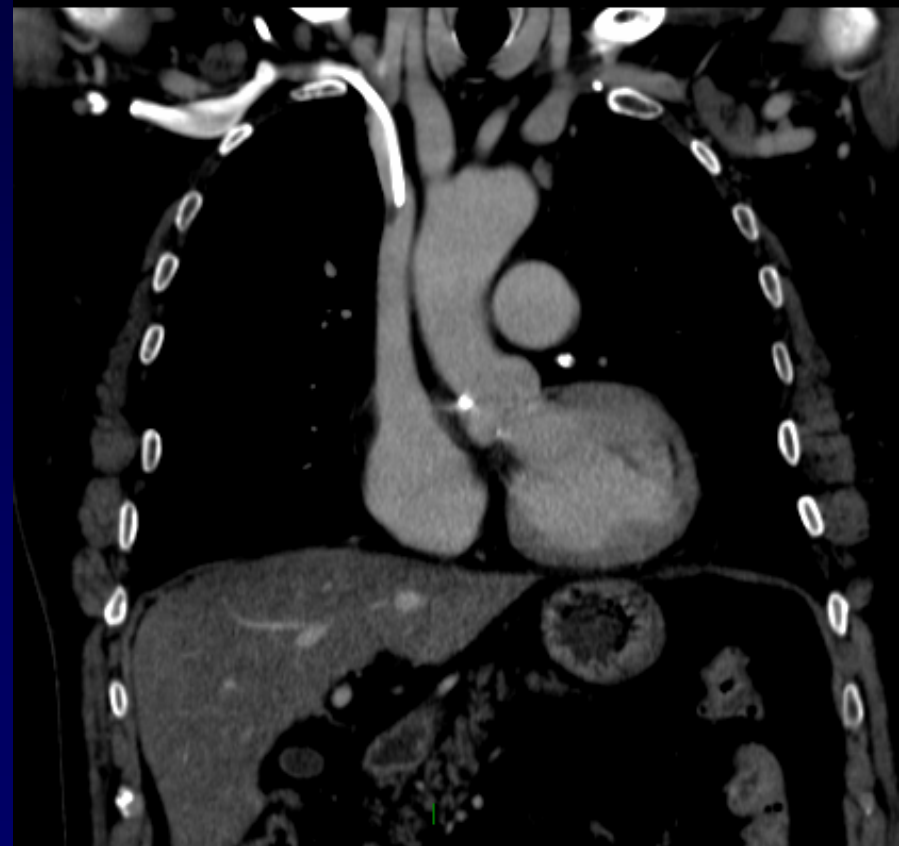

**Qu'en pensez vous ?**



## **DVI court**

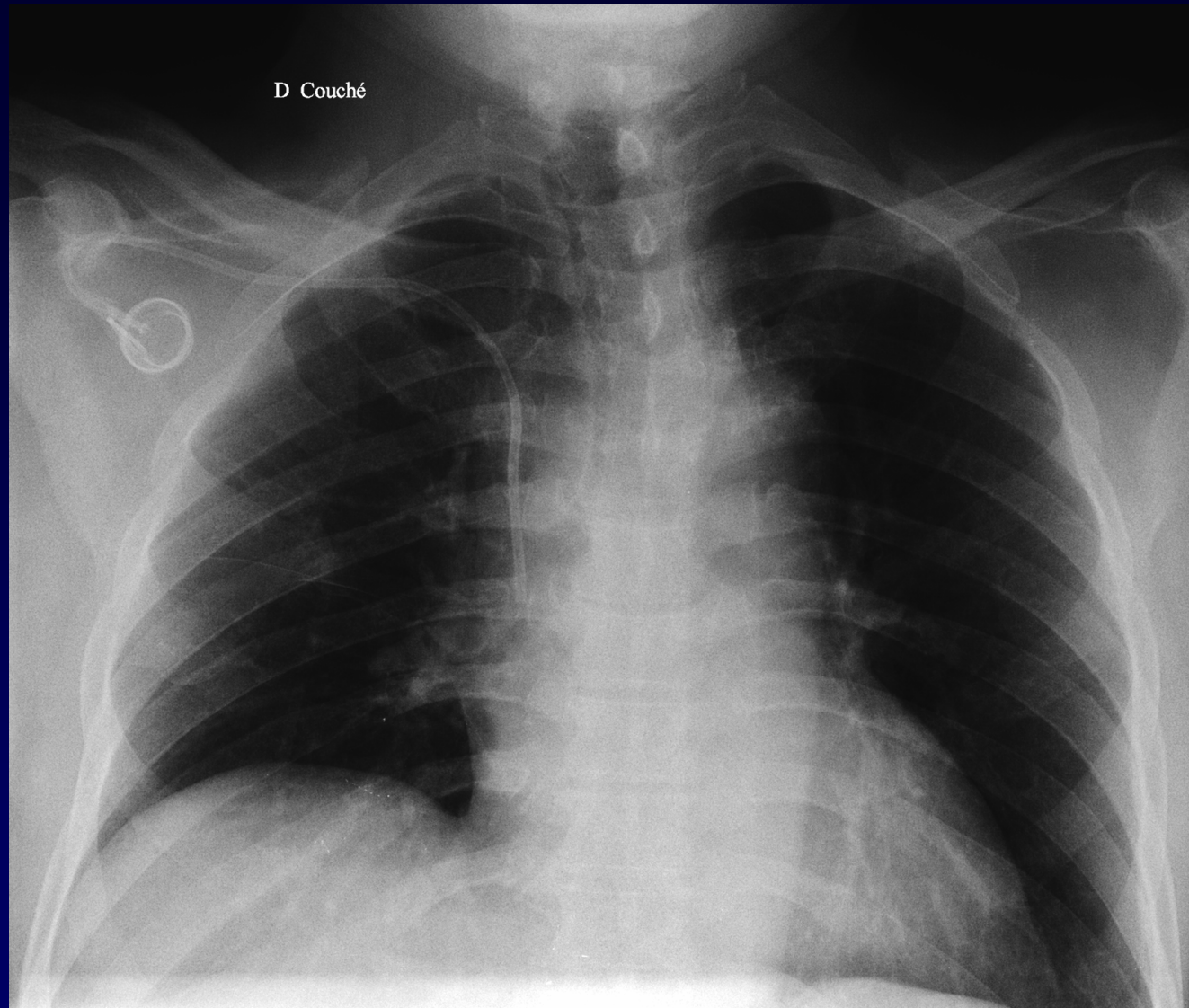
Thrombus cave supérieur  
suspendu au cathéter



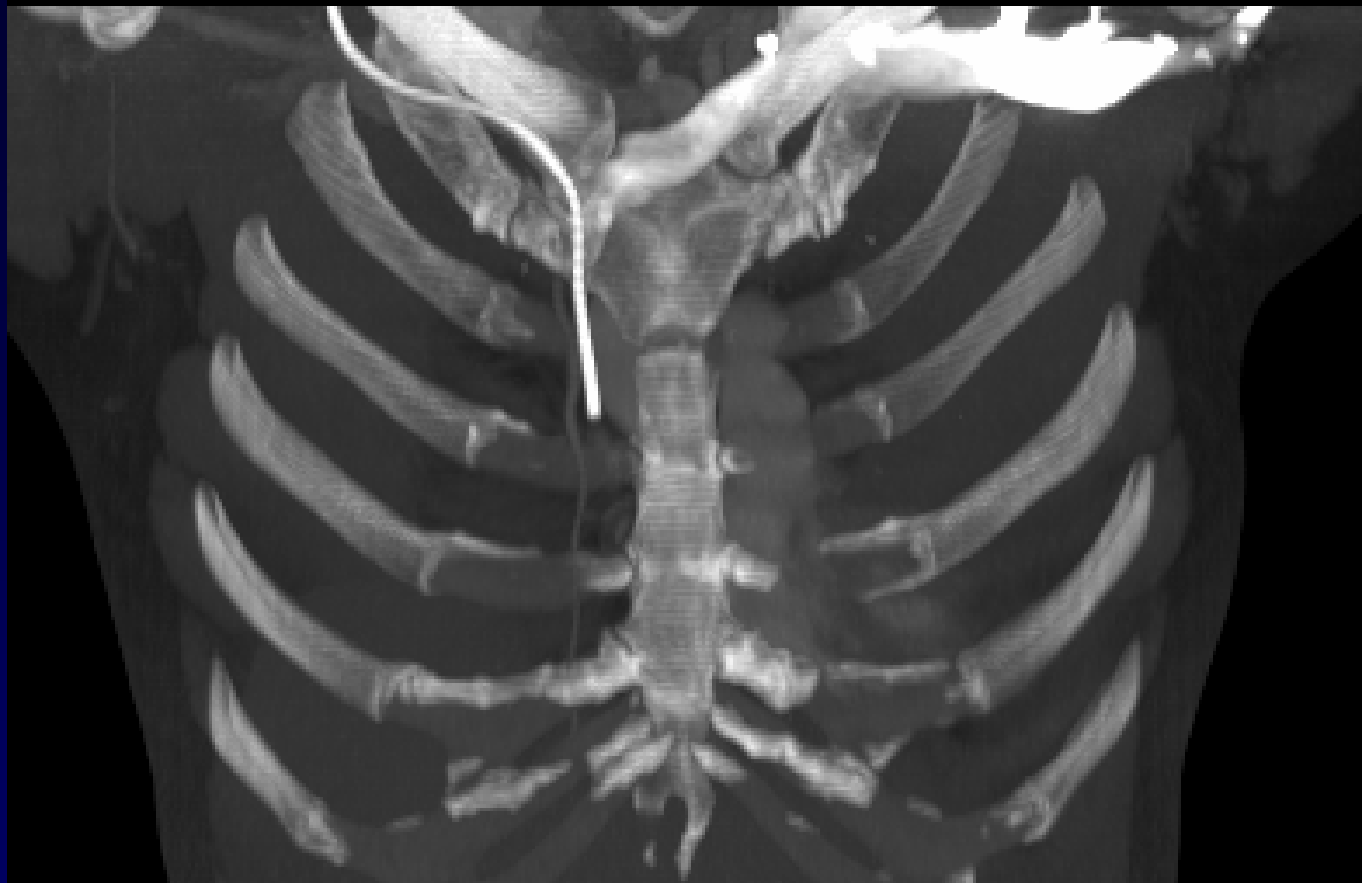



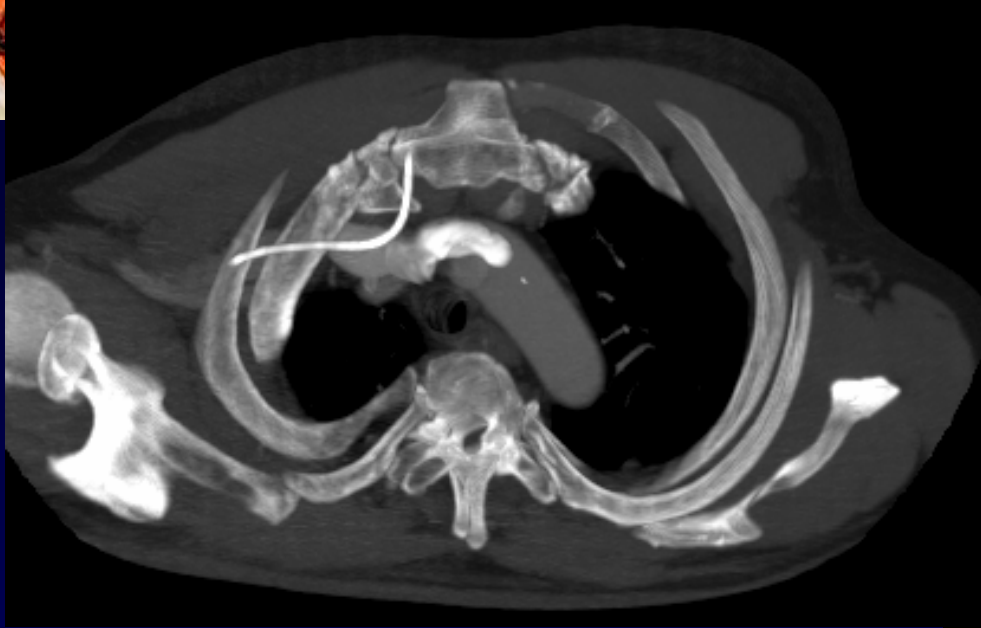## Cas 3



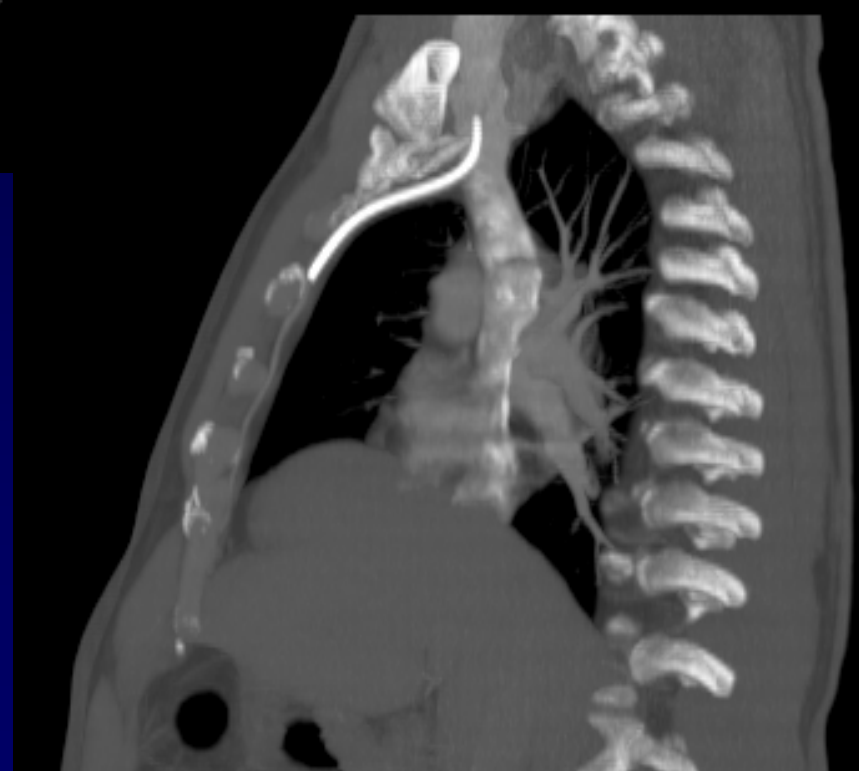**Qu'en pensez vous ?**



**Qu'en pensez vous ?**



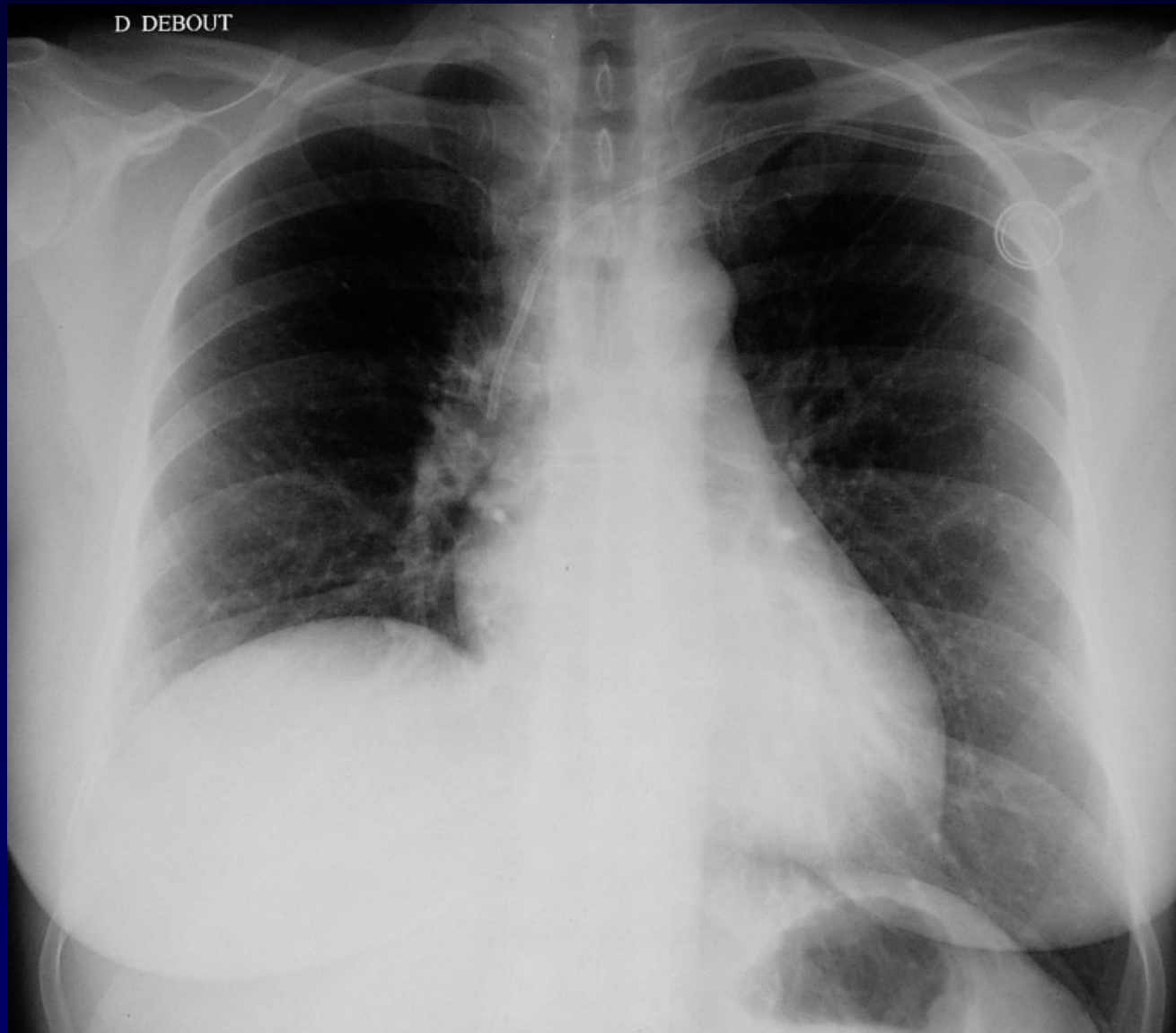
**DVI dans la veine thoracique  
Interne droite**



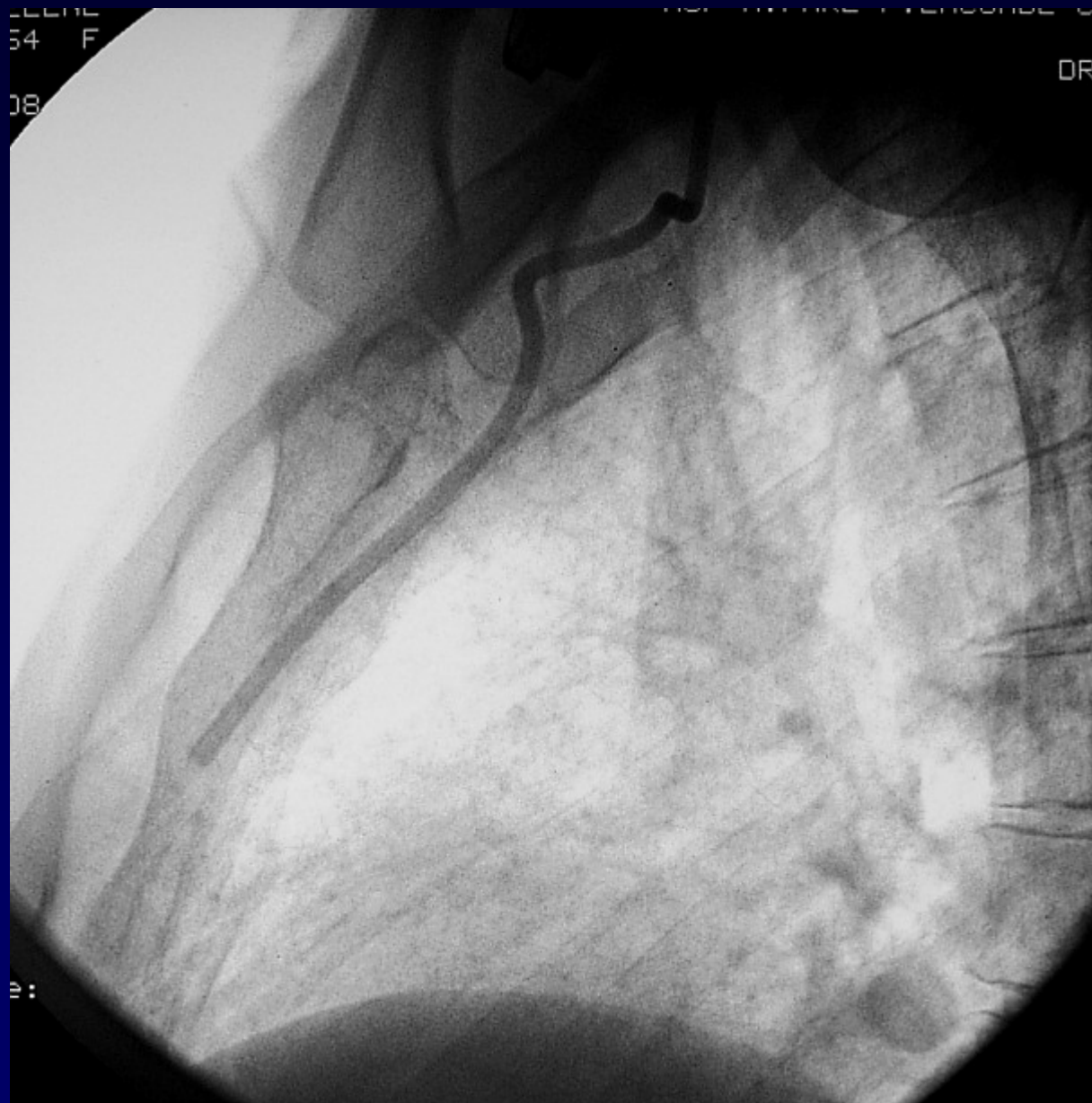



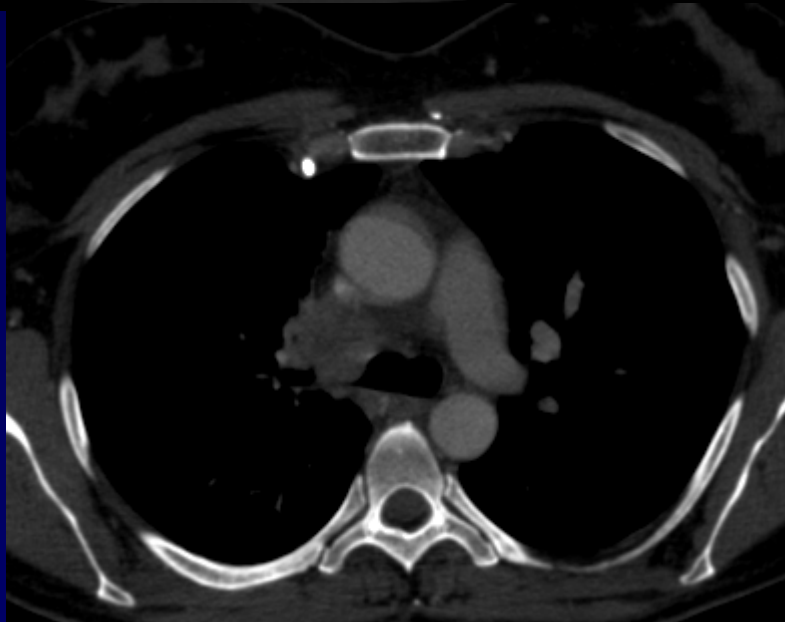
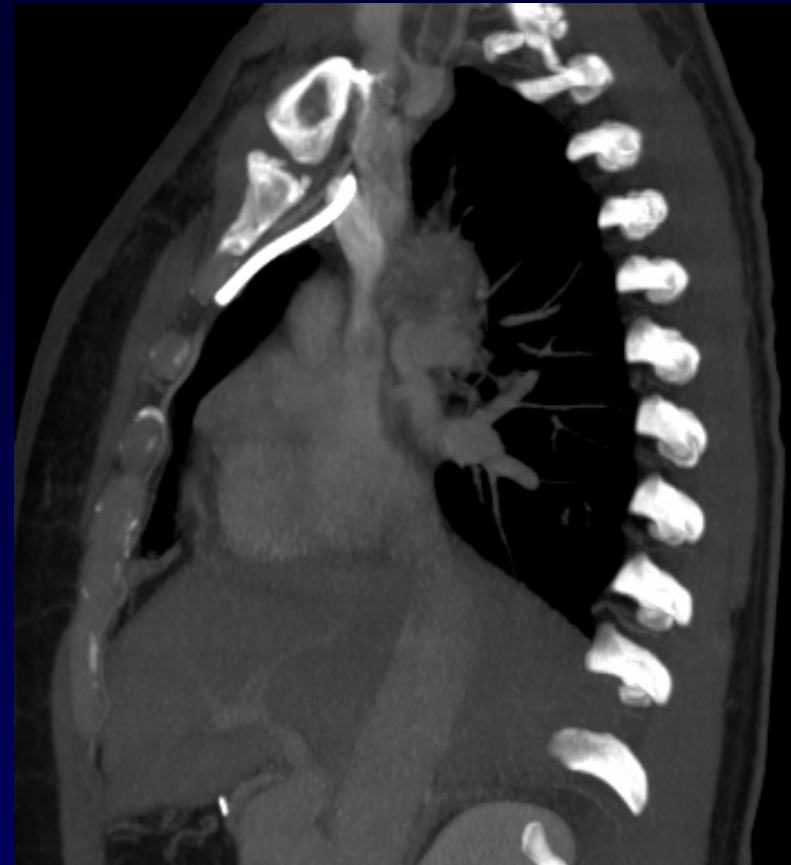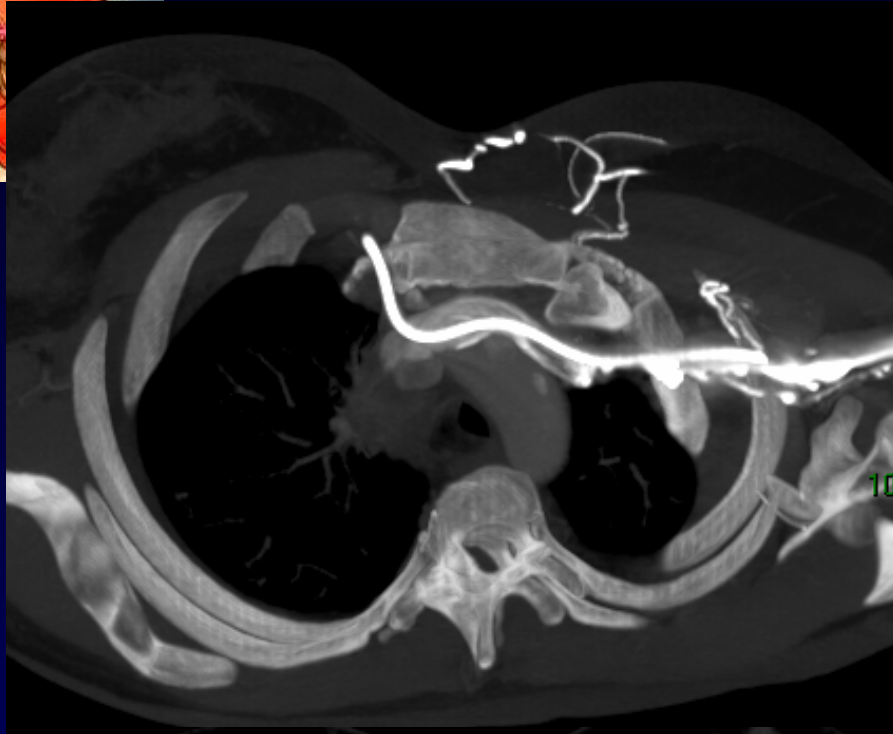## Cas 4

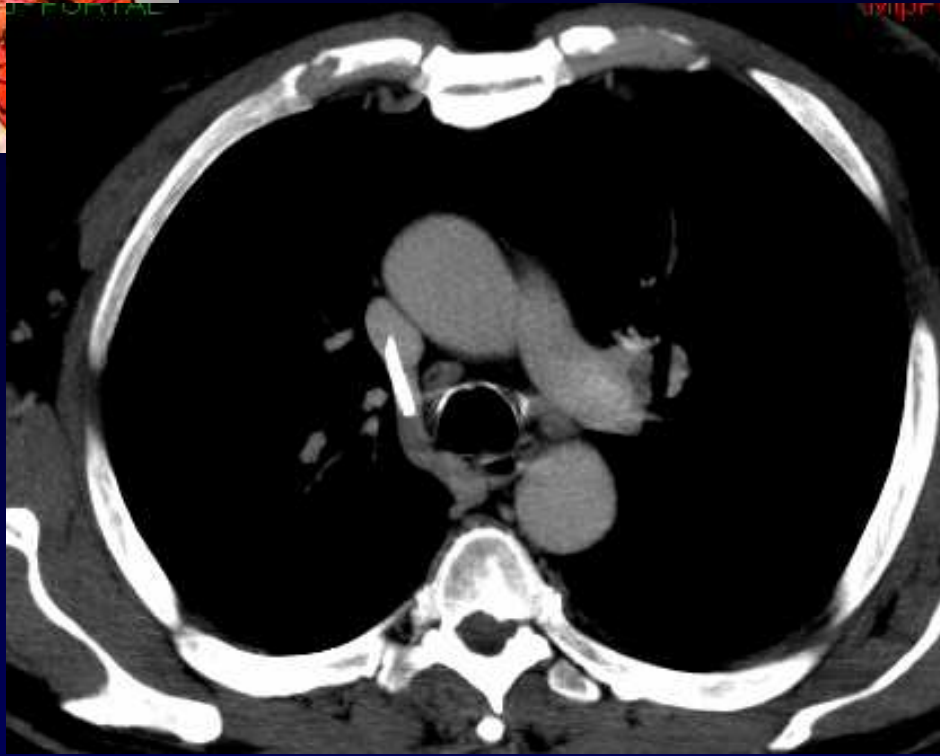


Qu'en pensez vous ?

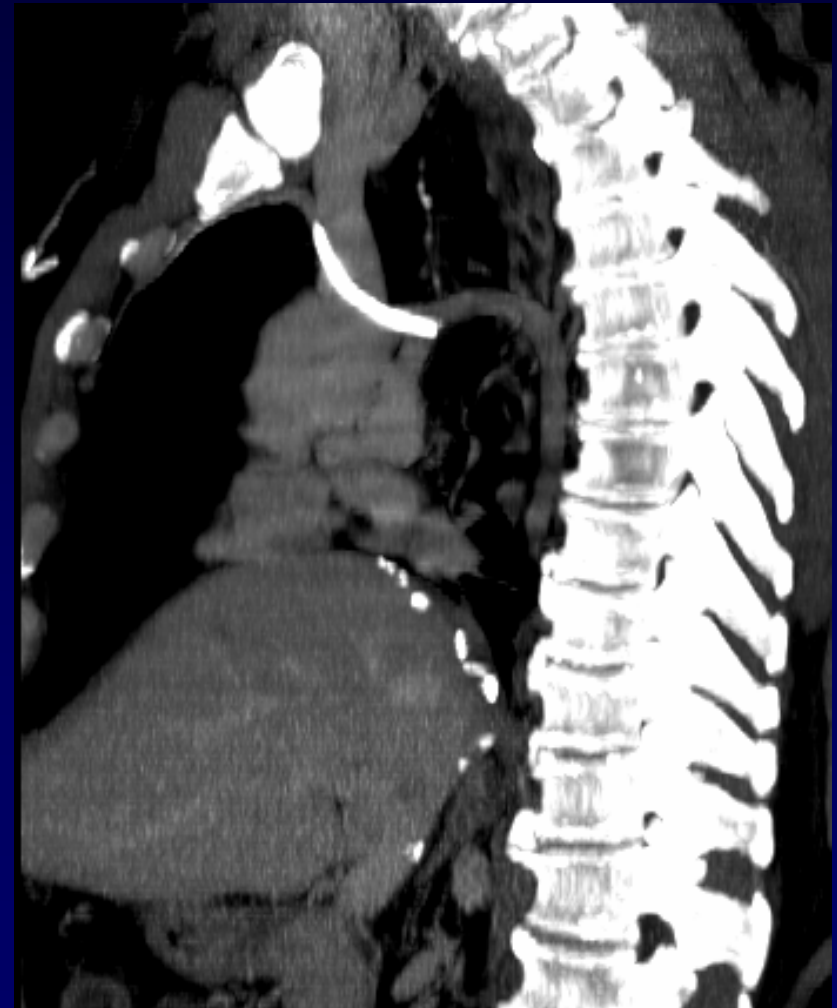



**DVI dans la veine thoracique  
Interne droite  
Syndrome cave supérieur malin**



## Cas 5

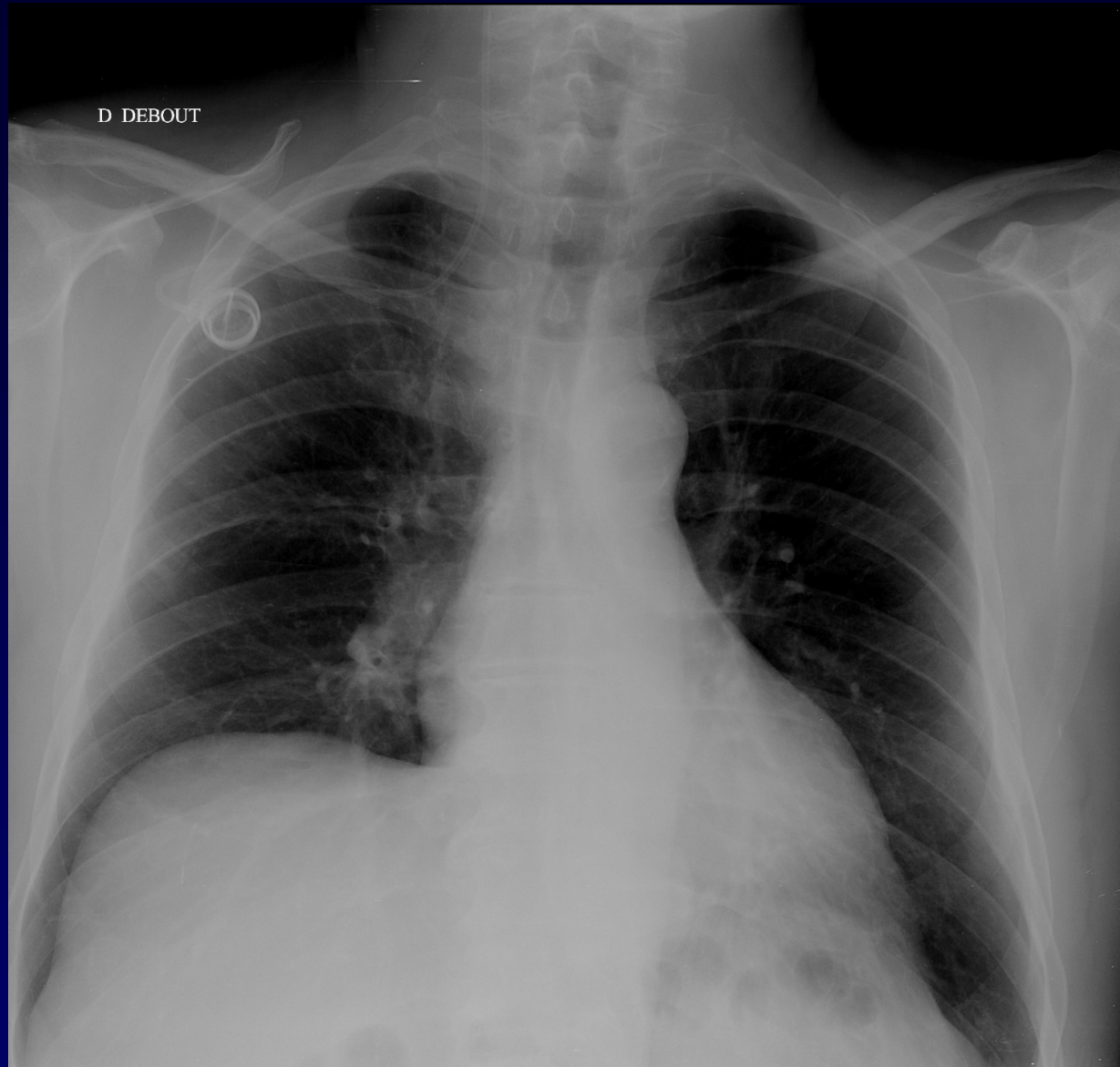


**DVI dans la veine azygos**






## Cas 6



**Qu'en pensez vous ?**

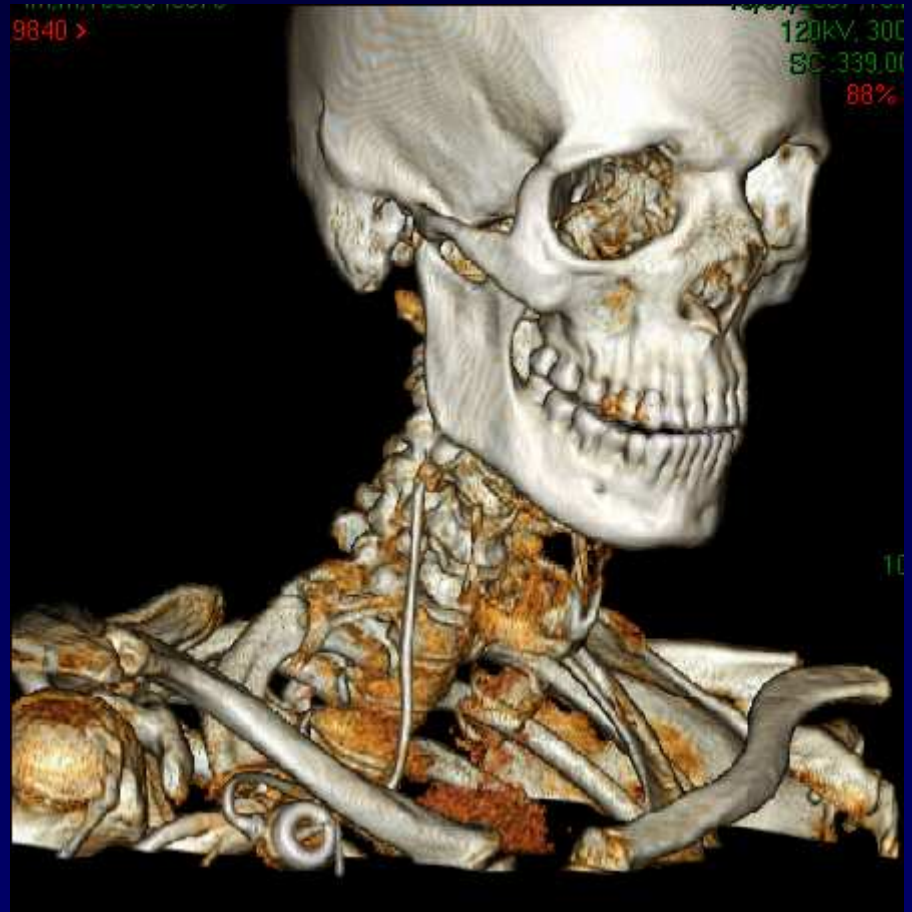
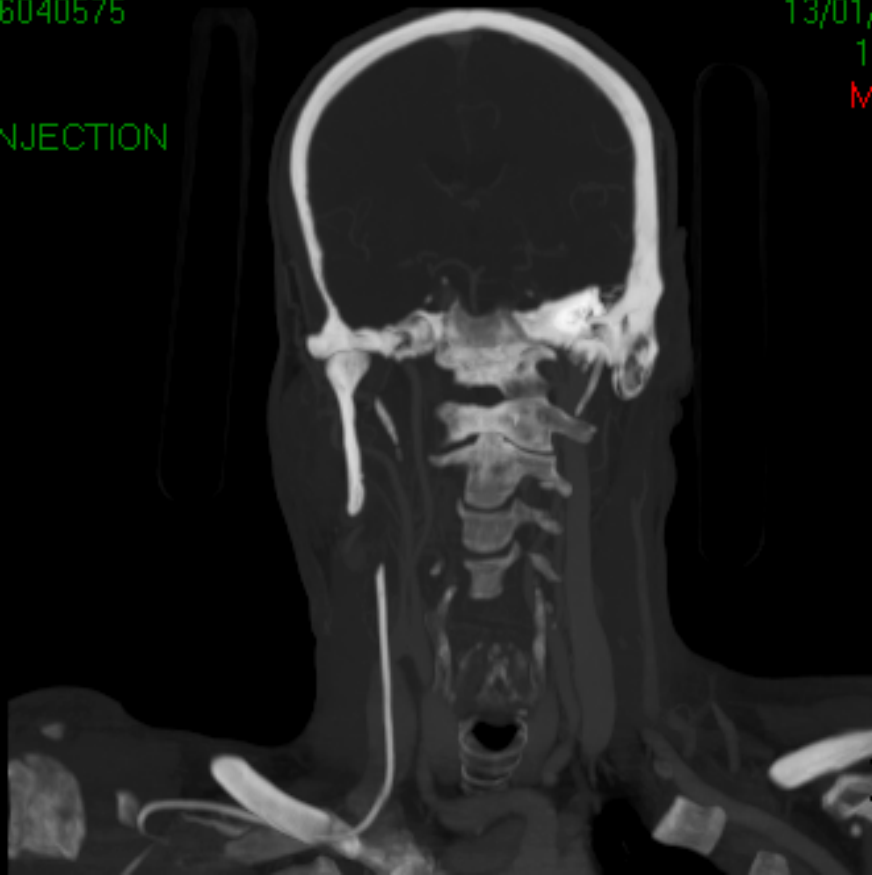




6040575

13/01/  
1;  
M

INJECTION



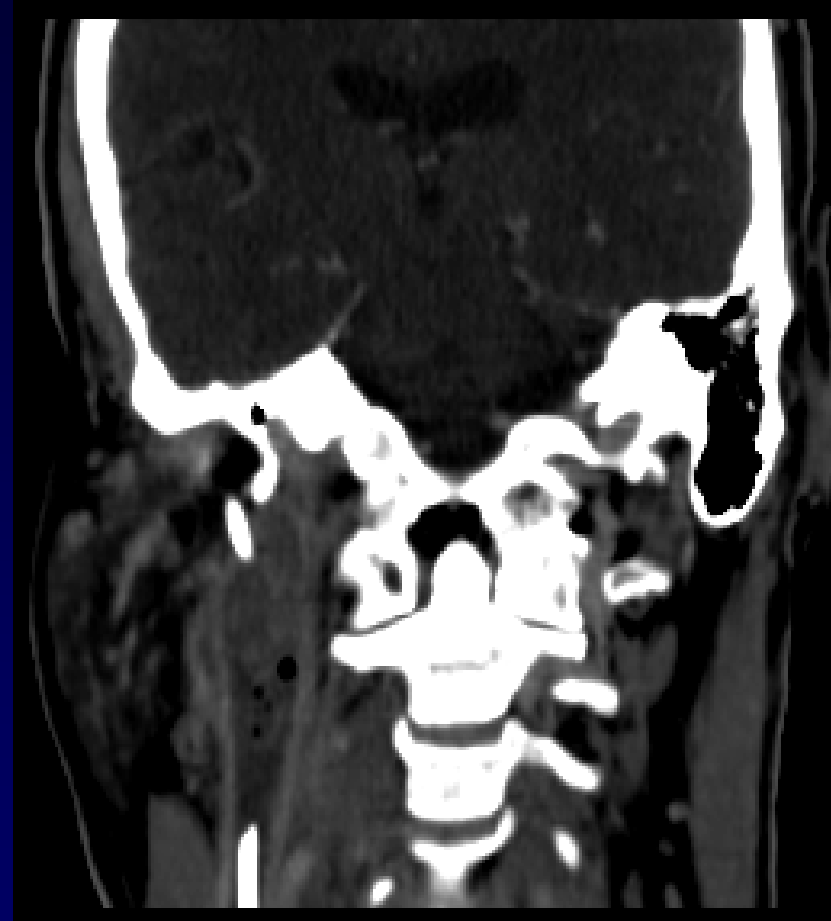9840 >

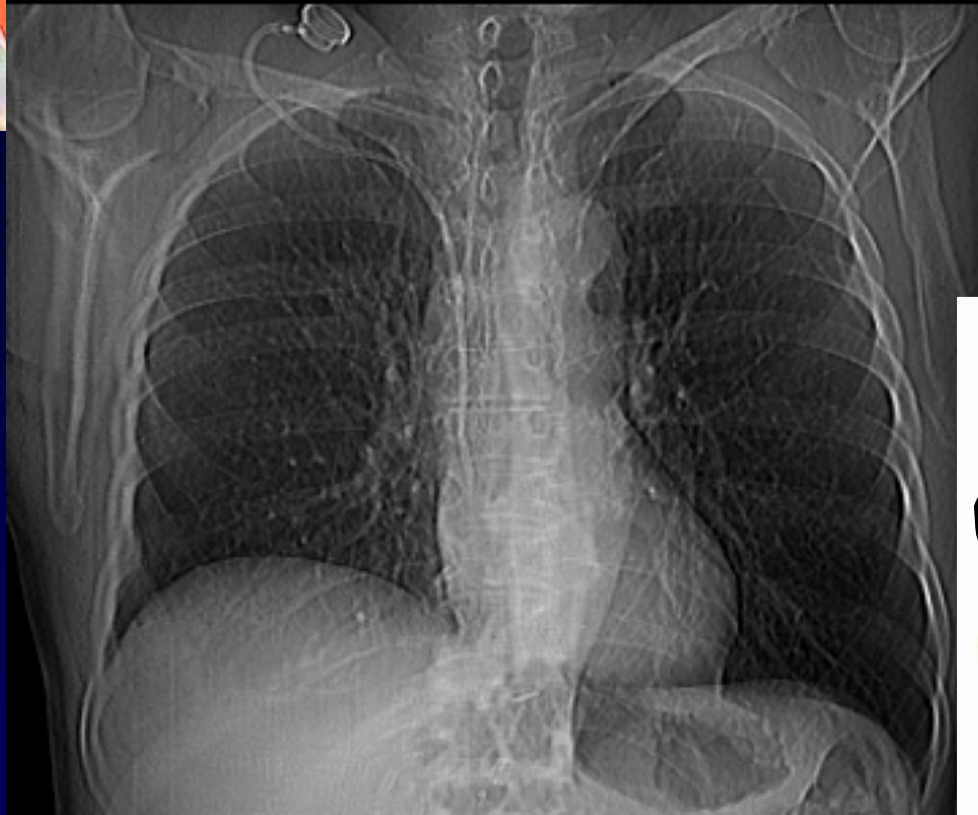
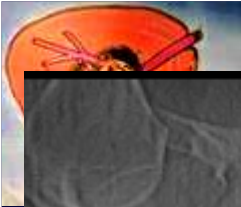
120kV, 300  
SC: 339.00  
88%

10



**DVI dans la veine jugulaire  
interne droite responsable  
d'une thrombose septique**





## Points à retenir

**Position normale d'un DVI**

=

Extrémité en dessous de la  
bronche souche droite  
À l'entrée de l'atrium droit

